NEUROLOGICAL

Network Training – 17.02.26

OVERVIEW

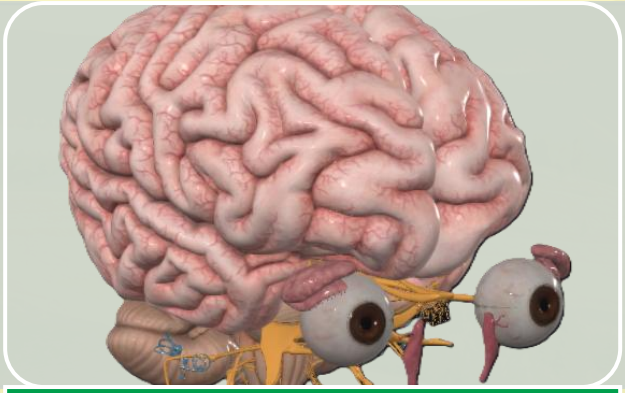

Anatomy



Conditions

Management

NAME THE BRAIN

List the most parts and functions of the neurological system.

You have 5 minutes.

Your time starts when Little Alex Horne runs away.

A TALE OF TWO ~~CITIES~~ SYSTEMS

(Motsinger, 2020)

- Nervous System (NS)
  - Peripheral NS
    - Somatic
    - Autonomic
  - Central NS
    - Brain
    - Spinal Cord

(Waugh, 2023)

(Motsinger, 2020)

BRIAN

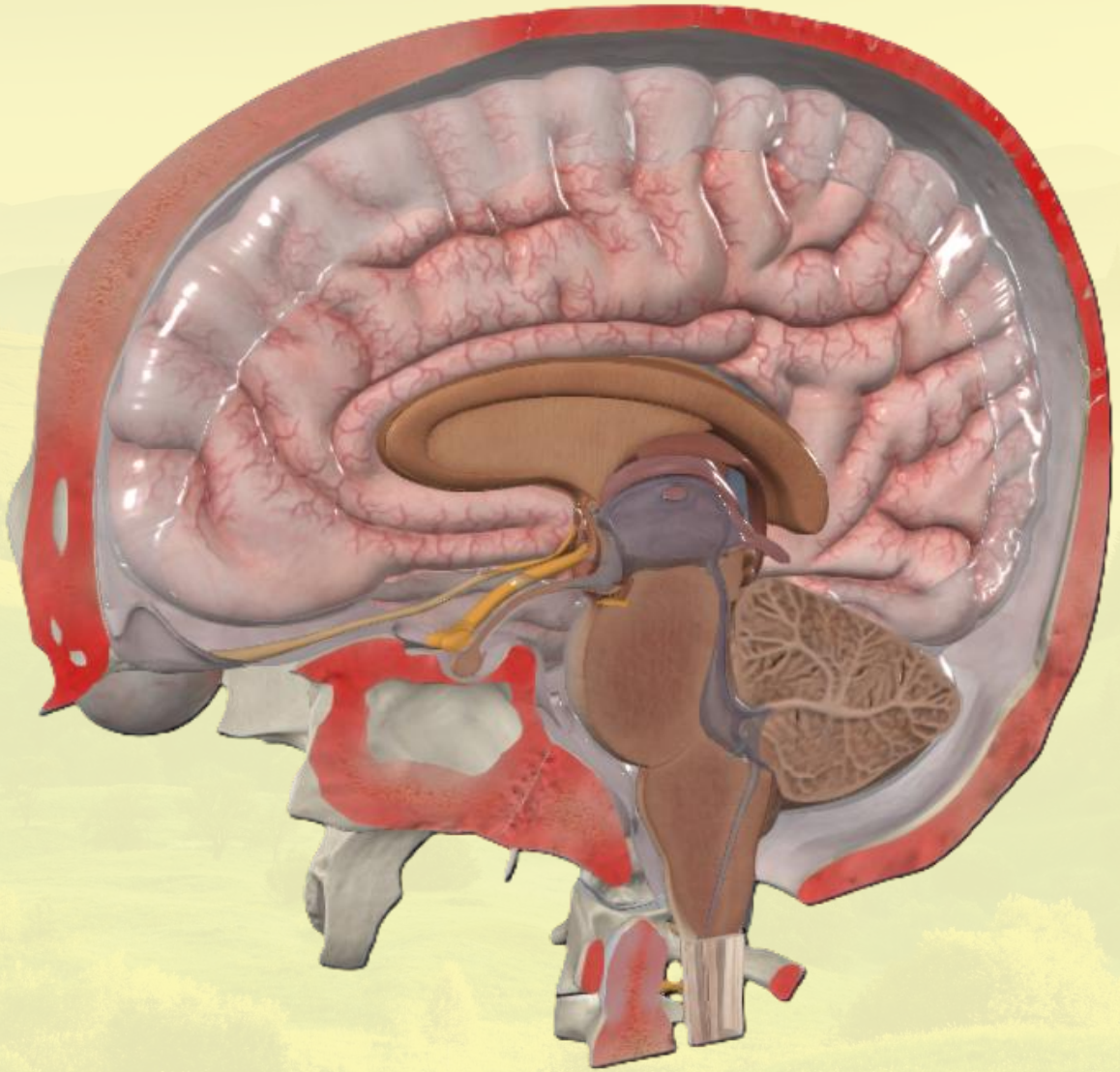

(Motsinger, 2020)

MENINGES

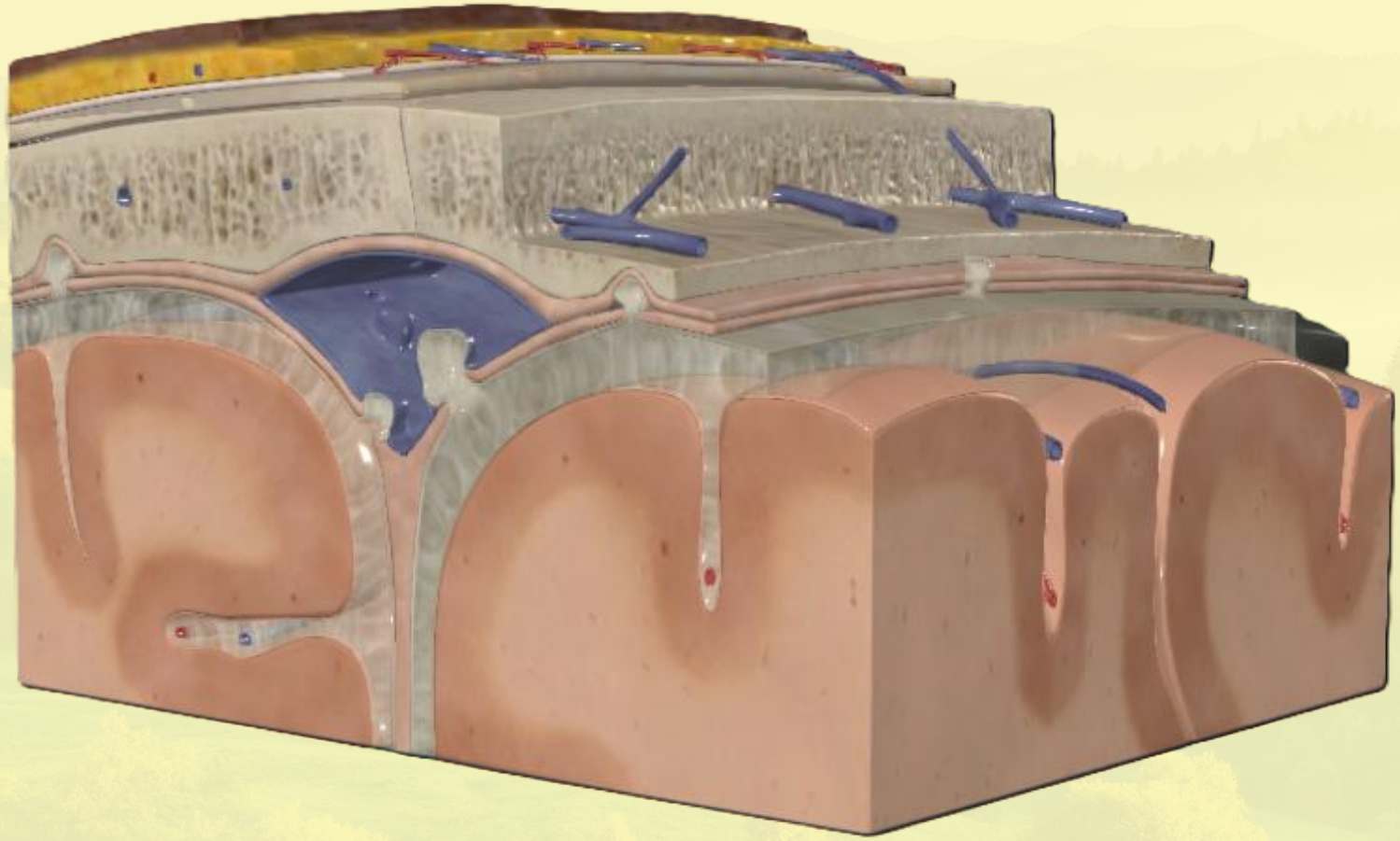

(Motsinger, 2020)

SPINAL CORD

Cervical → Thoracic → Lumbar → Sacral

(Motsinger, 2020)

PUPILS

(Pilbery & Lethbridge, 2019)

LEVEL OF RESPONSE

A — **Alert**
- Fully awake

C — **Confusion (new)**
- New-onset or worsening confusion

V — **Voice**
- Responds to verbal stimulus

P — **Pain**
- Responds to pain stimulus (e.g. supra-orbital pressure)

U — **Unresponsive**
- No response to verbal or pain stimulus

(Pilbery & Lethbridge, 2019)

Response	Criterion	Score
Eye-opening response (E)	Eye-opening spontaneously	4 points
	Eye-opening to sound	3 points
	Eye-opening to pain	2 points
	No response	1 point
Verbal response (V)	Orientated	5 points
	Confused	4 points
	Inappropriate words	3 points
	Incomprehensible sounds	2 points
	No response	1 point
Motor response (M)	Obeys command	6 points
	Localises to pain	5 points
	Withdraws to pain	4 points
	Abnormal flexion to pain (decorticate)	3 points
	Abnormal extension to pain (decerebrate)	2 points
	No response	1 point

(Jefferies, 2023; Yousuf & Heathcote, 2025)

CONDITIONS

CASE STUDY

- You have responded to a seizing patient at Manchester Pride. You have a tablet, AED, first aid kit, and oxygen barrel bag.
- The patient is led on the pavement and initial assessment shows them as unresponsive but breathing.
- Their arms and legs are rapidly moving in asymmetrical patterns. The movement increases and decreases in intensity over time. It's hard to tell, but it did seem to be more intense whilst you were assessing for pain response.
- Their eyes are tightly closed and cannot easily be opened.
- The seizing has lasted so far around **five minutes.**
- The person who called for help says:

"I only met them today; we'd been drinking and they suddenly walked off. I went looking for them and they were having an epileptic fit on the floor outside! It's just gotten worse since I arrived and just now it's gotten even further worse!"

(JRCALC, 2025)

SEIZURES

(JRCALC, 2025)

BLTCS (epilepsy)

Functional/ Dissociative Seizures (FND)

CASE STUDY

- It’s event season on Blackpool Promenade and one of the regular members of the public have come to speak to you just as the shift starts. Today you notice they seem a bit slow answering questions.
- When they speak, the words are understandable but slightly slurred. When you comment on this, they do admit to having a little to drink.
- To be safe, you ask them to smile, and their face looks fairly symmetrical, although you think the left side might be slightly weaker. It’s difficult to tell.
- You ask them to lift both arms. They can raise both arms, but after about 10 seconds the left arm drifts slightly downward.
- They say they have a bad headache and feel “not quite right”. They had a migraine earlier today which always leaves them feeling “a bit off” for the rest of the day.
- You check their pupils and they appear equal and reactive.
- They can walk normally but seem slightly unsteady.

(JRCALC, 2020)

Time = Brain

(Motsinger, 2020)

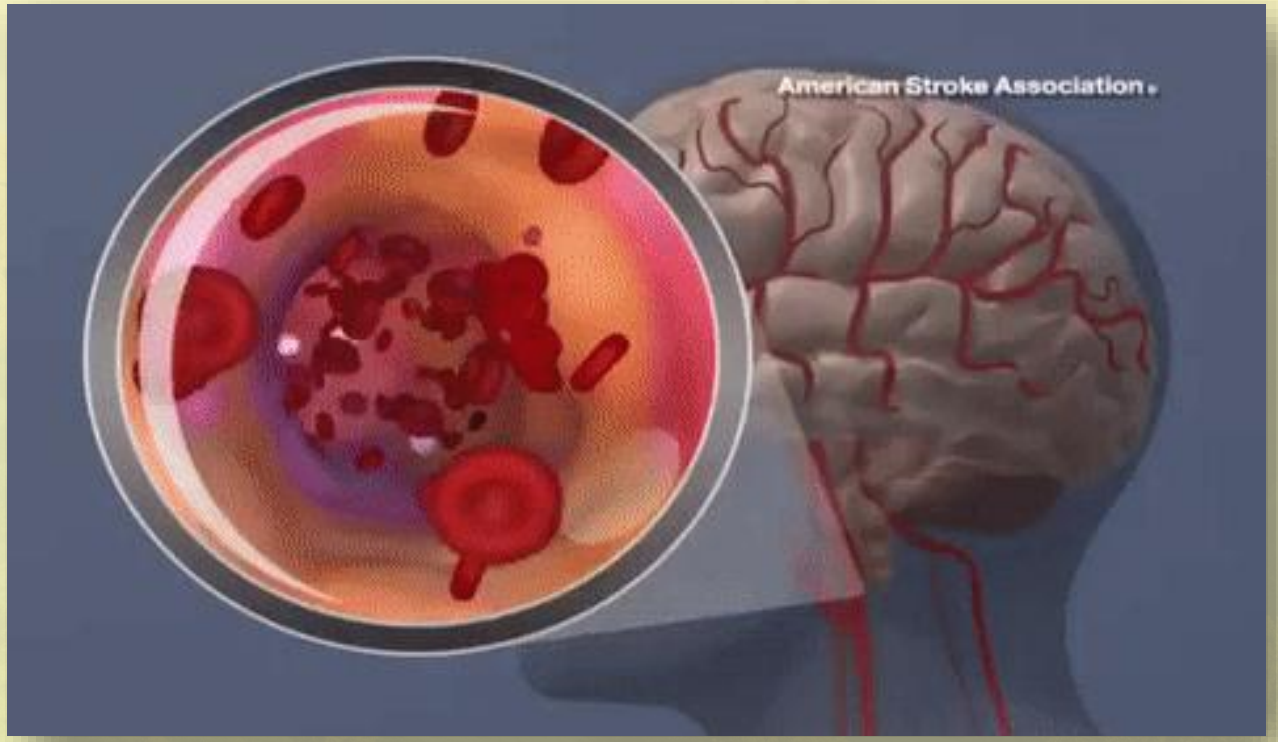

(JRCALC, 2020)

STROKE MIMICS

- seizures
- syncope
- sepsis
- hypoglycaemia
- migraine
- decompensation of previous stroke
- functional disorders

(JRCALC, 2020)

HEADACHES

(JRCALC, 2020)

Primary

- Tension
- Cluster
- Migraine

Secondary

- Medication Overuse
- Sub Arachnoid Haemorrhage

Table 3.69 – Red Flag Signs and Symptoms

- Headache localised to the vertex, i.e. top of the head.
- Escalating headache of an unusual nature.
- Changed visual acuity.
- Meningeal irritation, i.e. neck stiffness and photophobia.
- Cranial nerve palsy.
- Worsening headache with fever.
- Sudden-onset or thunderclap headache reaching maximum intensity within 5 minutes.
- New-onset neurological deficit, i.e. loss of function or altered sensation.
- New-onset cognitive dysfunction.
- Change in personality.
- Impaired level of consciousness.
- Recent head trauma, typically within the past three months.
- Headache triggered by cough, Valsalva (trying to breathe out with nose and mouth blocked) or sneeze.
- Headache triggered by exercise.
- Orthostatic headache, i.e. a headache that changes with posture.
- Symptoms suggestive of giant cell arteritis, which could include pain and tenderness over the temples, jaw pain while eating or talking and vision problems.
- Symptoms and signs of acute narrow-angle glaucoma, i.e. red eye.
- A substantial change in the characteristics of the headache.
- Vomiting without other obvious cause.
- Newly presenting ataxia, i.e. a neurological sign consisting of a lack of voluntary coordination of muscle movements.
- Any evidence of a rash.

(JRCALC, 2020)